

CHRISOFIX CHEST ORTHOSIS TECHNIQUE FOR A RIB FRACTURE PATIENT

Sevde Bengisu Yartaşı¹ , Ayşenur Çolakel¹ , İlayda Guluf¹ , Yekta Altemur Karamustafaoğlu² ¹Trakya University School of Medicine, Edirne, TÜRKİYE²Trakya University School of Medicine, Department of Thoracic Surgery, Edirne, TÜRKİYE

ABSTRACT

Thoracic trauma, which is frequently encountered in the field of thoracic surgery, is of great importance with its mortality and morbidity rates and is usually observed as multiple body trauma. The treatment of rib fracture, one of the most common findings of thoracic trauma, is usually in the form of pain control. In addition to the classical pain control methods, there is also a treatment method with the Chrisofix® Chest Orthosis, which is not yet used commonly. In this case report, we aimed to present the treatment of multiple rib fractures with Chrisofix Chest Orthosis in a patient who was admitted to our hospital. A 47-year-old female patient was admitted to our hospital with blunt thorax trauma after an in-vehicle car accident. On the first examination, the patient was conscious, cooperative, and her general condition was fair. The radiologic evaluation revealed fractures on the anterolateral side of the 3rd, 4th, 5th, and 6th ribs, a sternum fracture, and a minimal pneumothorax. In addition to the routine pharmacologic pain treatment and care, the Chrisofix Chest Orthosis was used for the repair of the fractures. The patient was successfully treated and discharged after three days of hospitalization. In this case, we concluded that the Chrisofix Chest Orthosis can be used on patients with multiple rib fractures, as it minimizes the complications, significantly reduces pain, and shortens the healing process.

Keywords: Rib fracture, Chrisofix Chest Orthosis, trauma

INTRODUCTION

Thoracic traumas constitute one-third of all trauma emergencies (1). Trauma is one of the most important causes of death, and thoracic trauma is the reason for 20-25% of deaths related to traumas (2). Thoracic traumas may affect many organs and systems. For this reason, it is of great importance to be treated as soon as possible. Flail chest is seen in 5% of thoracic traumas, which are caused by at least two fractures of at least three ribs (3). Mechanical ventilators are used in the flail chest treatment of rib fractures. It destabilizes the chest wall and reduces respiratory volume, thus causing restrictive and obstructive respiratory distress, as well as unforeseeable effects on bronchial secretion. Poor pain management can lead to pulmonary complications as a result of decreased ventilation (4). Pain management is crucial in rib fractures in order to stop the progression of the trauma. In this context, methods such as intravenous analgesia (non-

opioid analgesics, opioid analgesics, etc.), intercostal blockage, and patient-controlled analgesia are used (2). Chrisofix Chest Orthosis (CCO) is another method used for the treatment of rib fractures. In this case report, we aimed to assess the possible contribution of CCO to the treatment of traumatic rib fractures and in reducing the complications of a traumatized patient after an accident.

CASE REPORT

A 47-year-old female patient was admitted to the Trakya University School of Medicine Hospital with a blunt thorax trauma after an in-vehicle car accident. Tenderness was noticed on the affected side of the chest wall both on light and deep palpation. The patient was conscious, and cooperative, and her general condition was fair. The patient's first vital signs were normal (temperature: 36.4 °C, blood pressure: 126/80 mmHg,



Address for Correspondence: Sevde Bengisu Yartaşı, Trakya University School of Medicine, Edirne, TÜRKİYE

e-mail: bbengisyurts@gmail.com

ORCID iDs of the authors: SBY: 0000-0002-3334-3240; AÇ: 0000-0002-9879-7948; İG: 0000-0001-6964-3125; YAK: 0000-0002-5491-1219.

Received: 18.01.2022 Accepted: 18.05.2022

Cite this article as: Yartaşı SB, Çolakel A, Guluf İ et al. Chrisofix chest orthosis technique for a rib fracture patient. Turk Med Stud J 2022;9(2):67-9.

Copyright@Author(s) - Available online at <https://www.turkmedstudj.com/>



OPEN ACCESS

pulse: 78 beats per minute, SpO₂: 98%). The radiologic evaluation revealed fractures on the anterolateral side of the 3rd, 4th, 5th, and 6th ribs, a sternum fracture, and a minimal pneumothorax (Figure 1). Examinations of other systems were normal. Her ribs were not displaced. Transdermal remifentanyl 25 mg, oral paracetamol 500 mg 4x1, and N-acetylcysteine 600 mg were prescribed to the patient. The CCO was placed on the fracture region in order to reduce pain and paradoxical chest movements

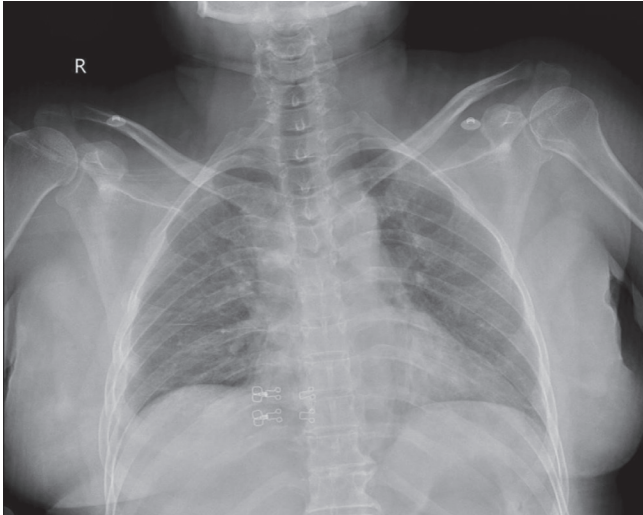


Figure 1: Posteroanterior chest radiography revealing 3rd, 4th, 5th, and 6th rib fractures on the right side on the day of the accident.

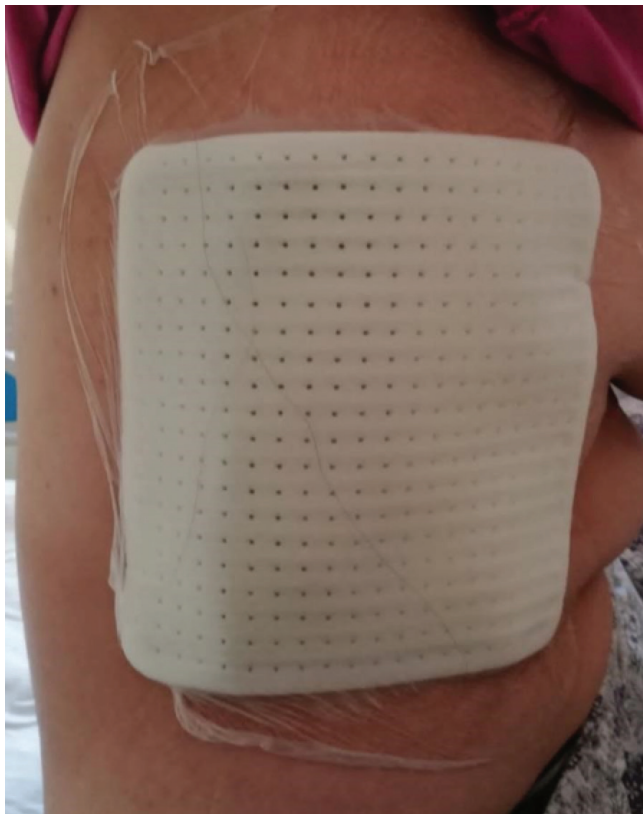

Figure 2: Chrisofix Chest Orthosis placement on the fracture region.

(Figure 2). The pain was significantly reduced compared to the first day [third-day visual analog score: 3, first-day visual analog score: 9 (In visual analog scale higher scores indicate worse pain)]. After three days of hospitalization, the patient was discharged in a healthy condition. An informed verbal consent form was obtained from the patient.

Application of CCO

According to the official instructions of CCO, the body hair has to be removed and the skin has to be cleaned. The splint needs to be adjusted to the chest so that the direction of the arrow follows the ribs. The splint should be applied to the fracture region. The splint has to bridge the fractured area. It can be fixed on the area by removing the cover sheet from the bottom of the foil and pressing adhesive foil edges to the skin. It is appropriate to apply CCO in multiple consecutive rib fractures of the anterior and lateral chest, consecutive upper 1-8 ribs, and more than three rib fractures.

Initially, the application of a CCO reduces pain by stabilizing the fracture site that can simultaneously increase vital capacity and reduce pain. It decreases the paradoxical thoracic movement, if present, and thus reduces the risk of late complications. Patients often try to manage their pain by applying pressure to the injured area using their hands, lying on their injured side, or by using belts. The innovation of CCO, the rib splint, mimics this pressure applied by the hand. CCO rib splint decreases the movements of the thereby decreasing the pain. Less pain helps the injured patient take adequately deep breaths to promote ventilation.

DISCUSSION

Rib fractures are the most common types of injuries to the thorax following blunt chest trauma, and they are identified in nearly 10% of all trauma patients (5). It can be caused by falls, traffic accidents, crush injuries, and coughing (6, 7). In this case, we reported a 47-year-old female patient with a total of 4 rib fractures on the right side caused by an in-vehicle car accident. The patient had a flail chest and minimal pneumothorax. A flail chest is defined as three or more consecutive rib fractures in two or more places identifiable by computer tomography and X-ray. Flail components result in paradoxical movement of the flail segment, making it move inward while the other parts of the thoracic cage during inspiration expand out. This limits lung expansion and leads to less effective ventilation (8). As the number of rib fractures increases, the higher rates of pneumonia, aspiration, pneumothorax, and duration of hospitalization may occur. Patients with flail chest and several rib fractures might require ventilator management, and intensive pain control to decrease the risk of further complications. However, none of these methods are adequate only by themselves for the treatment of rib fractures. Surgical rib fixation is a method for repairing rib fractures. Even though this method has been used for years, it may lead to rare but concerning postoperative complications. These surgical rib fixation related complications are emphysema, surgical site infection, persistent effusion, or

hematoma. Prolonged hospitalization, pneumonia, prolonged ventilation, or death are the general thoracic trauma-related complications. It is difficult to distinguish whether these complications are a result of the surgical fixation or the thoracic injury itself (9). Therefore, the CCO was designed as an alternative method. CCO is one of the therapeutic approaches to treat rib fractures besides these standard treatments. We applied CCO on the day of trauma. This application aims to shorten the duration of hospitalization, reduce analgesic usage, improve pain management and reduce the number of pulmonary complications (4). According to a meta-analysis, patients treated with CCO spend 2.2 days less in the hospital, compared to the control group (10). We concluded that CCO binding is beneficial in terms of a short duration of hospitalization, as we have observed in our patient who had six days of hospitalization and experienced reduced pain and analgesic consumption. The CCO method shows a lot of promise, yet it is an underused application that still needs to be worked on.

The usage of CCO in the management of rib fractures aims to improve the quality of life and the functional abilities of patients as soon as possible.

Ethics Committee Approval: N/A

Informed Consent: Verbal informed consent was obtained from the patient.

Conflict of Interest: The authors declared no conflict of interest.

Author Contributions: Concept: S.B.Y., A.Ç., İ.G., Y.A.K., Design: S.B.Y., A.Ç., İ.G., Y.A.K., Supervision: S.B.Y., A.Ç., İ.G., Y.A.K., Resources: S.B.Y., A.Ç., İ.G., Y.A.K., Materials: S.B.Y., A.Ç., İ.G., Y.A.K., Data collection and/or Processing:

S.B.Y., A.Ç., İ.G., Y.A.K., Analysis and/or Interpretation: S.B.Y., A.Ç., İ.G., Y.A.K., Literature Search: S.B.Y., A.Ç., İ.G., Y.A.K., Writing Manuscript: S.B.Y., A.Ç., İ.G., Y.A.K., Critical Review: S.B.Y., A.Ç., İ.G., Y.A.K.

Financial Disclosure: The authors declared that this study received no financial support.

REFERENCES

1. Sarıtaş A, Kul C, Kandış H et al. Traumatic bilateral pneumothorax: three case reports. *Konuralp Medical Journal* 2011;3:28-31. [Crossref]
2. Tekinbaş C, Eroğlu A, Kürkçüoğlu İC et al. Chest trauma: analysis of 592 cases. *Ulus Travma Acil Cerrahi Derg* 2003;9:275-80. [Crossref]
3. Çobanoğlu U. Chest trauma: analysis of 110 cases. *Turk Thorac J* 2006;7:162-9. [Crossref]
4. Lee Y, Lee SH, Kim C et al. Comparison of the effectiveness in pain reduction and pulmonary function between a rib splint constructed in the ER and a manufactured rib splint. *Medicine (Baltimore)* 2018;97:e10779. [Crossref]
5. Çiftçi H. Retrospective analysis of patients operated by flail chest. *Euroasia Journal of Mathematics, Engineering, Natural & Medical Sciences* 2020;7:112-8. [Crossref]
6. Sano A, Tashiro K, Fukuda T. Cough-induced rib fractures. *Asian Cardiovasc Thorac Ann* 2015;23:958-60. [Crossref]
7. Martin TJ, Eltorai AS, Dunn R et al. Clinical management of rib fractures and methods for prevention of pulmonary complications: a review. *Injury* 2019;50:1159-65. [Crossref]
8. Coary R, Skerritt C, Carey A et al. New horizons in rib fracture management in the older adult. *Age Ageing* 2020;49:161-7. [Crossref]
9. Senekjian L, Nirula R. Rib fracture fixation: indications and outcomes. *Crit Care Clin* 2017;33:153-65. [Crossref]
10. Mészáros T, Sárvány A, Petri A et al. Use of chest orthosis can significantly shorten the hospitalisation of rib fracture patients. 7th European Trauma Congress. Ljubljana, Slovenia; 2006.p.279-82. [Crossref]