

CHALLENGES IN DIAGNOSING RENAL INFARCTION: A CASE REPORT

Enisa Mustavataj¹ , Eda Shundo¹ , Zeynep Turna¹ , Ferdi Karagöz² , Burak Günay³ , İlhan Kurultak² 

¹Trakya University School of Medicine, Edirne, TÜRKİYE

²Trakya University School of Medicine, Department of Internal Medicine, Division of Nephrology, Edirne, TÜRKİYE

³Trakya University School of Medicine, Department of Radiology, Edirne, TÜRKİYE

ABSTRACT

We aimed to present a renal transplant recipient who did not undergo regular follow-up and therefore developed renal infarction. However, we aim to emphasize that post-transplantation lactate dehydrogenase levels should be carefully monitored. A 28-year-old male patient with chronic hypertension and a history of kidney transplantation was admitted to Trakya University School of Medicine, Department of Nephrology with the diagnosis of cellular renal transplantation rejection. Physical examination showed normal vital signs. No abnormality was detected in urinalysis, urine culture, and urine microscopic examination. Blood tests revealed increased creatinine and urea levels without a significant increase in lactate dehydrogenase levels at baseline. As an additional diagnostic tool, Doppler ultrasonography imaging was performed, which revealed normal renal parenchyma and anatomical features without any evidence of arterial stenosis. Electrocardiography and investigation of troponin levels were requested. Cardiologic findings were normal and no intervention was required. Finally, a contrast-enhanced computed tomography scan of the abdomen and pelvis was performed with the suspicion of renal infarction. A sickle-shaped hypodense area was observed in the renal anteroposterior cortex, and a diagnosis of renal infarction was made. Renal infarction is a difficult disease to diagnose because of its non-specific symptoms. Careful monitoring of lactate dehydrogenase levels after transplantation is necessary, as elevated lactate dehydrogenase levels are very common in renal infarction cases and acute transplant rejection may be associated with subclinical vasculitis.

Keywords: Infarction, lactate dehydrogenase, creatinine, renal transplantation

INTRODUCTION

Renal infarction is a rare condition caused by impaired blood flow in the renal artery. It is an underdiagnosed phenomenon with unclear pathophysiological features (1). Although not all patients have the same symptoms, abdominal pain, groin pain and hypertension are the most common symptoms (2). It mimics the pathological features of various diseases such as renal colic, pyelonephritis, and pulmonary embolism without specific clinical findings (3).

The most common cause of renal infarction is of cardioembolic origin, but it has been reported that most of the cases are idiopathic (4). A postmortem study performed in Los Angeles

among patients aged from 4 months to 88 years revealed that the incidence of renal infarction was 1.4% (205 of 14,411), where only 2 of the 205 were diagnosed antemortem (5).

Delayed diagnosis of renal infarction may cause irreversible damage to the kidney tissue and increase the risk of mortality by triggering embolic events that can affect other organs (1). Contrast-enhanced computed tomography (CECT) is used for the diagnosis of renal infarction (3).

With this case report we aim to present a case of renal artery infarction having no specific clinical findings and mimicking the pathological features of various diseases. Along with that, we aim to emphasize that post-transplantation lactate dehydrogenase



Address for Correspondence: Zeynep Turna, Trakya University School of Medicine, Edirne, TÜRKİYE

e-mail: xyzturna@gmail.com

ORCID iDs of the authors: EM: 0000-0001-7758-5359; ES: 0000-0002-2586-3887; ZT: 0000-0001-6868-5059; FK: 0000-0001-9656-6970; BG: 0000-0002-8462-7681; İK: 0000-0001-5607-13750.

Received: 24.12.2021 Accepted: 14.04.2022

Cite this article as: Mustavataj E, Shundo E, Turna Z et al. Challenges in diagnosing renal infarction: a case report. Turk Med Stud J 2022;9(2):64-6.

Copyright@Author(s) - Available online at <https://www.turkmedstudj.com/>



OPEN ACCESS

levels should be carefully monitored. Additionally, we would like to emphasize the importance of regular follow-ups.

CASE REPORT

A 28-year-old male patient with a history of chronic hypertension and a renal transplant was admitted to the nephrology department of an external center with groin pain, burning during urination, and headache. The patient had not gone through regular follow-up after the renal transplant. While the physical examination was normal, laboratory tests revealed an increase in the creatinine level from 1.2 mg/dL to 2.8 mg/dL. Due to the increase in the creatinine level, a renal biopsy was performed, and the patient was diagnosed with cellular renal transplant rejection. Following the diagnosis, the patient was given 250 mg of intravenous pulse steroid, and the per oral (PO) tacrolimus dose was increased from 2 mg to 3.5 mg daily. The patient was admitted to the nephrology department of the Trakya University School of Medicine for further examination.

On physical examinations, the patient's vital signs were within the normal range. Urinalysis, urine culture, and urine microscopic examination revealed no abnormalities. A stool culture was requested because the patient had diarrhea. The blood tests revealed that the patient's creatinine (2.52 mg/dL) and urea (64 mg/dL) levels were increased. There was no significant increase in lactate dehydrogenase (LDH) level. As further diagnostic tools, ultrasonography and Doppler ultrasonography were performed, revealing normal renal parenchymal and anatomical features without any evidence regarding arterial stenosis. Electrocardiography and the investigation of troponin levels were requested after the patient expressed complaints such as chest pain and bounding pulse. Cardiological findings were normal, and no interventions were found necessary.

During hospitalization, the patient developed abdominal sensitivity, primarily at the right lower quadrant where the renal transplantation was performed. The blood tests were requested again. It revealed that the LDH level was increased to 361 U/L (Table 1). With the exacerbation of the patient's complaints, renal Doppler ultrasonography was performed with the suspicion of renal infarction.

The patient started a treatment dose of 0.4 mg of subcutaneous (SC) clexane twice daily, which allowed the patient's pain to subside. With the findings of renal Doppler ultrasonography, the possibility of renal arterial stenosis was ruled out. In addition, CECT scanning was required. The CECT scanning of the abdomen and pelvis showed that the pelvicalyceal system

of the transplanted kidney was slightly prominent. At the renal anteroposterior cortex, a sickle-shaped hypodense area was observed, and the patient was diagnosed with renal infarction (Figure 1).

Moreover, minimal effusion was observed at the periphery of the transplanted kidney and pericardial area. Anti-cardiolipin antibodies, anti-b2-glycoprotein antibodies, protein C, protein S, and antithrombin 3 were requested to investigate whether there was another factor predisposing to infarct development. The antibody results were negative, so PO 5 mg of coumadin was included in the treatment in addition to the clexane the patient was receiving. During his stay in the hospital, urea levels changed between 90-100 mg/dL and creatinine levels 2.4-2.8 mg/dL. The patient was discharged with the recommendation of

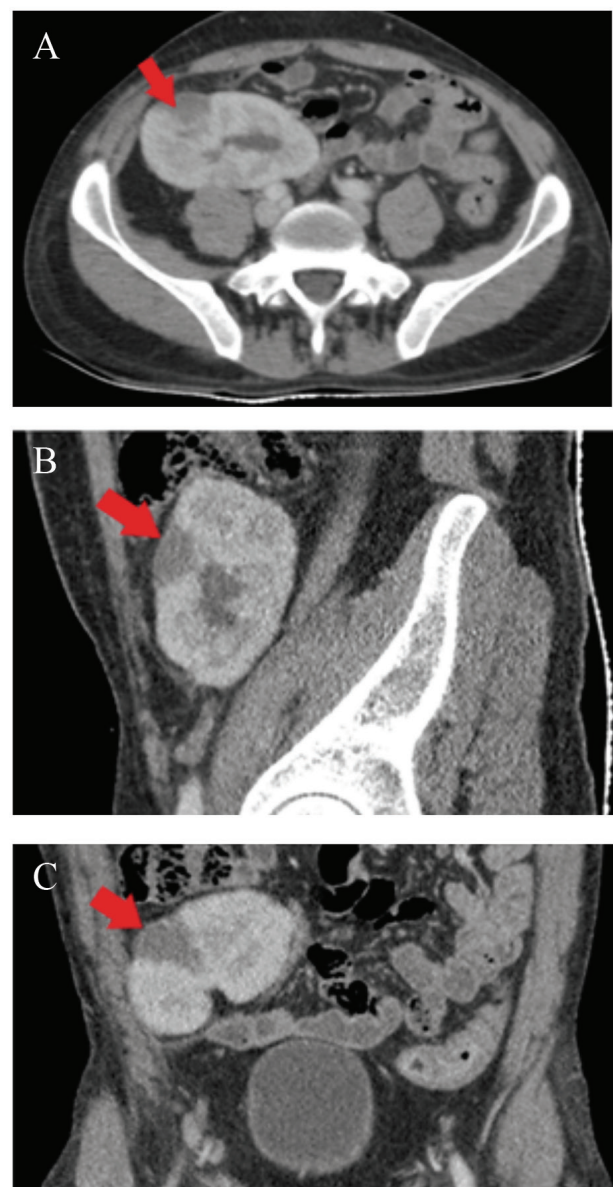


Figure 1: Contrast-enhanced computed tomography images reveal a sickle-shaped hypodense area at the renal anteroposterior cortex (red arrows). A: Axial plane, B: Sagittal plane, C: Coronal plane.

Table 1: Changes in the lactate dehydrogenase levels during the patient's hospitalization.

	Lactate dehydrogenase (U/L)
Reference range	0-247
Day of hospitalization (16.07.2021)	219
During hospitalization (12.08.2021)	361
Day of discharge (16.08.2021)	200

Table 2: Complete blood count and serum biochemistry.

	Reference range	Day of hospitalization (16.07.2021)	Day of discharge (16.08.2021)
Complete blood count			
White blood cells (10 ⁹ /L)	4.23-9.07	11.2	12.19
Red blood cells (10 ¹² /L)	4.63-6.08	4.48	3.53
Hemoglobin (g/dL)	13.7-17.5	12.4	9.6
Hematocrit (%)	40.1-51.0	36.2	28.3
Serum biochemistry			
Urea (mg/dL)	17-43	64	91
Creatinine (mg/dL)	0.72-1.25	2.52	2.46

control after 1 week. Blood test results of the patient on the day of hospitalization and discharge are shown in Table 2. Moreover, the patient's discharge prescription was as follows: tacrolimus PO 8.5 mg, mycophenolate mofetil PO 500 mg twice daily, prednisolone PO 5 mg once three days, amlodipine PO 10 mg once a day, famotidine PO 40 mg once a day, clexane SC 0.4 mg twice a day.

DISCUSSION

As in our patient, abdominal pain, inguinal pain, and hypertension are common findings in more than 50% of patients with renal infarction (1). Nausea, vomiting, and fever are among the less common symptoms (6). The aforementioned findings may also be present in pyelonephritis, renal colic, or pulmonary embolism (3). High LDH is one of the most important markers in the differential diagnosis of renal infarction (7). High creatinine is considered a marker of kidney damage (7).

Renal infarction is a difficult disease to diagnose because of its non-specific symptoms. Acute transplant rejection may be associated with subclinical vasculitis, which may be one of the causes of renal infarction (8). High LDH levels have been reported in 90.5% of renal infarction cases, therefore, we would like to emphasize that careful monitoring of post-transplant LDH levels is required (1). Renal artery infarction should be considered in every patient presenting with abdominal pain and renal dysfunction. As a result, CECT scanning should be requested for a more accurate evaluation of renal artery infarction (3).

Ethics Committee Approval: N/A

Informed Consent: Informed verbal consent was obtained from the patient.

Conflict of Interest: The authors declared no conflict of interest.

Author Contributions: Concept: E.S., Design: E.M., B.G., Supervision: F.K., İ.K., Data Collection and/or Processing: F.K., E.M., Analysis and/or Interpretation: E.M., E.S., Z.T., Literature Search: E.M., E.S., Z.T., Writing Manuscript: E.S., E.M., Z.T., Critical Review: E.S., E.M., Z.T.

Financial Disclosure: The authors declared that this study received no financial support.

REFERENCES

- Bourgault M, Grimbert P, Verret C et al. Acute renal infarction: a case series. *Clin J Am Soc Nephrol* 2013;8:392-8. [\[Crossref\]](#)
- Markabawi D, Singh-Gambhir H. Acute renal infarction: a diagnostic challenge. *Am J Emerg Med* 2018;36:1325.e1-2. [\[Crossref\]](#)
- Antopolsky M, Simanovsky N, Stalnikowicz R et al. Renal infarction in the ED: 10-year experience and review of the literature. *Am J Emerg Med* 2012;30:1055-60. [\[Crossref\]](#)
- Mesiano P, Rollino C, Beltrame G et al. Acute renal infarction: a single center experience. *J Nephrol* 2017;30:103-7. [\[Crossref\]](#)
- Hoxie HJ, Coggin CB. Renal infarction. Statistical study of two hundred and five cases and detailed report of an unusual case. *Arch Intern Med* 1940;65:587-94. [\[Crossref\]](#)
- Al-Shareef AS, Alwafi E, Alzailaie M et al. Idiopathic renal infarction: an important differential diagnosis of unexplained flank pain. *Cureus* 2021;13:e18206. [\[Crossref\]](#)
- London IL, Hoffsten P, Perkoff GT et al. Renal infarction. Elevation of serum and urinary lactic dehydrogenase (LDH). *Arch Intern Med* 1968;121:87-90. [\[Crossref\]](#)
- Nasr M, Sigdel T, Sarwal M. Advances in diagnostics for transplant rejection. *Expert Rev Mol Diagn* 2016;16:1121-32. [\[Crossref\]](#)